

PE Thrombectomy Inari FlowTrievers

January 20, 2021



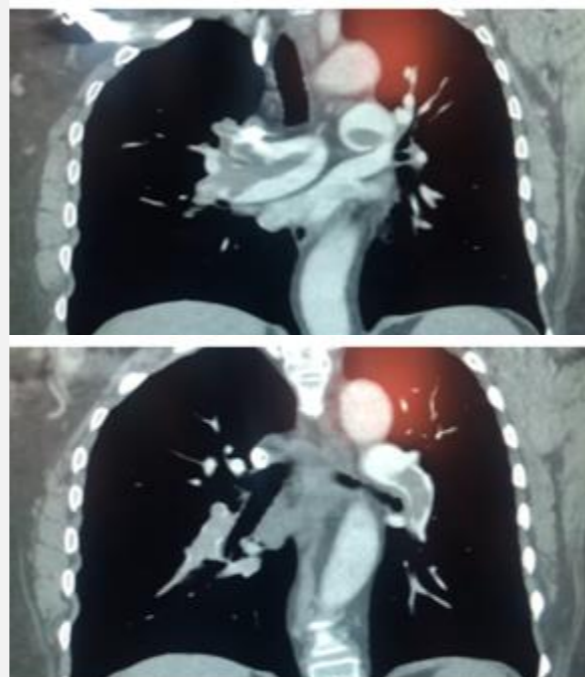
Dr. Vincent Flanders, MD
Interventional Radiology
Northwest Radiology



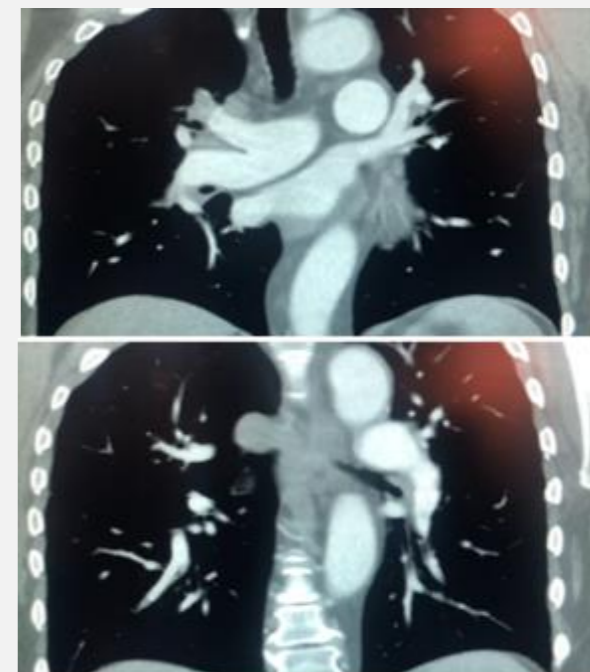
Patient/Procedural Notes

- Age: 71 Female
- Bilateral Saddle PE confirmed via CT
- US guided access of right femoral vein
- .035" J-wire wire and swan ganz balloon tipped catheter selected right PA
- PA gram confirmed significant clot in right main, interlobar, and TA
- 4 aspirations with T24 yielded significant clot on the right
- Left main selected
- 3 more aspirations yielded more clot
- Final venogram confirmed significant thrombus removal
- 40 min. case time
- 0 lytics used
- PA Pressures:
 - Right: Pre 55/13/33 Post: 37/9/22
 - Left: Pre 50/14/22 Post 20/4/16
- HR: 102 to 89

Pre
CTA



Post
CTA



Thrombus
Removed

